

Intestinal Perforation due to Tapeworm: *Taenia Solium*

NARAYAN SHRIHARI, MARIRAJ J., KUMUDINI T.S., KRISHNA S.

ABSTRACT

The infestation with tapeworm is a major problem in many parts of the world. A majority of the patients are asymptomatic and do not have serious sequelae. However, sometimes they can cause serious problems like intestinal obstruction due to the entanglement of the worms and the migration of the segments, which may cause appendicitis and intestinal perforation. The infection with *Taenia solium* is caused due to the ingestion of

under cooked pork meat which contains cysticercus cellulosae. The scolex is released after the digestion of the cysticercus which attaches to the intestinal mucosa and starts budding off segments. We received the tapeworm segments from the Department of Surgery. The segments were obtained during emergency exploratory laparotomy of a patient with intestinal perforation and the tapeworm segments were identified as that of *Taenia solium* in our laboratory.

Key Words: Cysticercus Cellulosae, Scolex

INTRODUCTION

Tape worms (*Taenia solium*) reside in the human small intestine and the patients experience discomfort and a perianal sensation (when the proglottids force their way through the anus) or sometimes vague abdominal discomfort, nausea, vomiting, anorexia, weakness and weight loss [1]. Neurocysticercosis has a tremendous impact on the human health and *Taenia solium* is the source of cysticercosis cellulosae in human beings [1]. The entangled worms of *Ascaris lumbricoides* may cause intestinal obstruction. Other worms which are reported to cause intestinal perforation are *Enterobius vermicularis*, *Trichuris trichura* and *Taenia solium* [2]. A review of the relevant literature of the past 10 years did not reveal many causes for the parasitic infestation of the intestinal perforations. *Taenia solium* is a rare cause of intestinal perforation [3]. The incidence of the tapeworm infection can be reduced by proper preventive measures and antihelminthic drugs [2].

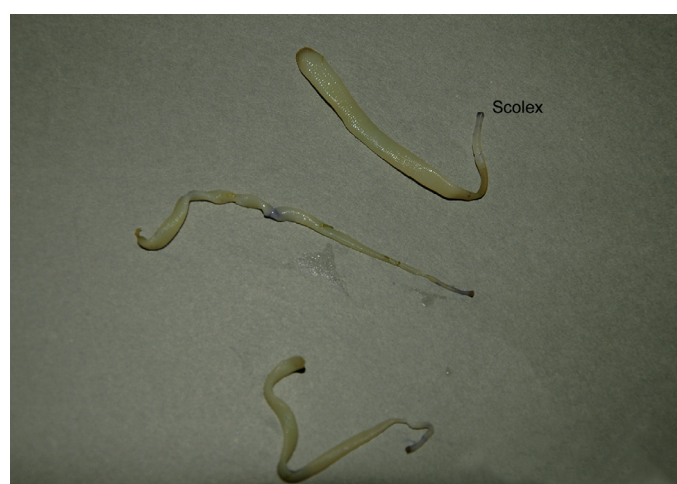CASE HISTORY

A 60 years old male presented with a sudden onset of abdominal pain which was initially mild but progressively severe and localized to the lower abdomen. He also gave a history of an on and off mild abdominal pain since two years, added a history of passing worms in the stool and elicited a diet history of pork meat consumption. On examination, his abdomen was found to be diffusely tender with guarding and rigidity, but no distension and bowel sounds were present. The patient was clinically diagnosed to have peritonitis which was secondary to a hollow, viscous perforation. His general physical examination and blood parameters were within normal limits, except for RBS which was 56mg/dl. His chest X-ray showed gas under the right dome of the diaphragm. An emergency exploratory laparotomy was performed, with primary closure of the ileal perforation and evacuation of the tape worm segments. The patient was treated with primary antibiotics and intra venous fluids for five days and later with oral praziquantel 600mg. He was discharged on his request and was advised for follow up. We identified scolices (head end of the tapeworm) [Table/Fig-1] from

the group of segments [Table/Fig-2]; each scolex measured 1mm in diameter and possessed four suckers and rostellum with hooks. A rostellum is a projection on the top of the scolex. The gravid segment measured 11mm in length and 6mm in breadth and an average of all the gravid segments had a length which was twice its breadth. With the help of an insulin syringe, we injected India ink into the central uterine stem of the proglottid, thus filling the uterine branches with ink. We observed seven lateral branches on each side of the uterine segment under a low power dissecting microscope. After squeezing the gravid segment between two slides, we could see the *Taenia* ova [Table/Fig-3 & 4]. Finally, we reported it as *Taenia solium*, due to the presence of the *Taenia solium* scolex which is seen in adult worms and indicated the species as solium due to the presence of the *Taenia solium* proglottid.

DISCUSSION

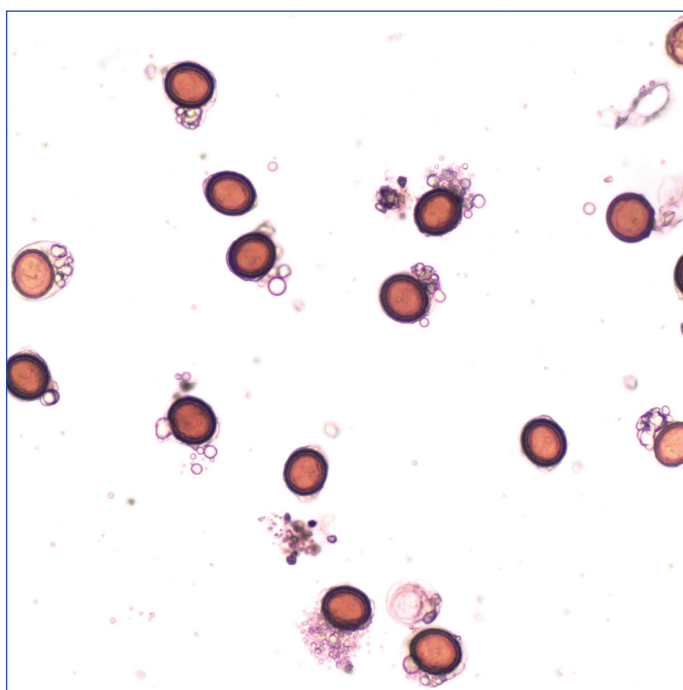
The prevalence of Taeniasis in the tropical zones is high. Most of the patients ended up with severe surgical complications with a high morbidity and mortality [3]. The incidental presence of tapeworms in



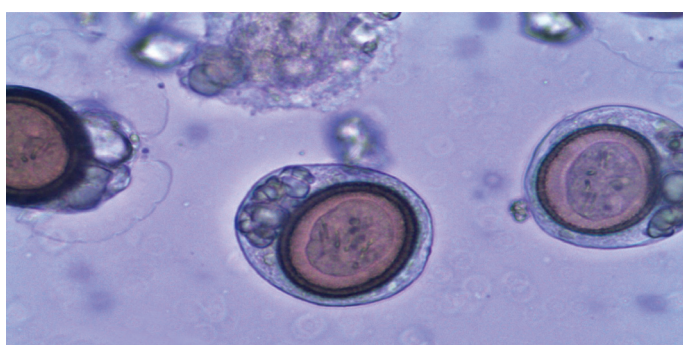
[Table/Fig-1]: Head end of tape worm



[Table/Fig-2]: Extracted tape worms



[Table/Fig-3]: Taenia ova from the proglottid (low power)



[Table/Fig-4]: Taenia ova from the proglottid (high power)

the bowel lumen contributes considerably to the bowel perforation. In doubtful cases, a diagnostic laparotomy should be done [3]. We are reporting a rare case of intestinal perforation due to tapeworm (*Taenia solium*) and a similar case was reported by Khan Z also [2].

Taenia solium is a ribbon like, segmented, flat worm which resides in the small bowel of human beings. Each worm consists of a scolex (head), a neck and multiple segments (proglottids) and has an independent reproductive capability [4]. The terminal half of the

worm consists of mature gravid segments. These segments are muscular and can detach and crawl out through the anal sphincter. The gravid segments break off and are passed in the faeces, which contaminate water, soil and grass. If ingested by pigs (the intermediate hosts) the segments are digested, thus releasing thousands of eggs. The eggs hatch and release the larvae which penetrate the wall of the pig intestine and reach the skeletal muscles via the blood circulation [2, 5]. Here, the larvae develop into cysts (cysticercus cellulosae). When the human beings eat undercooked infected pork meat, the cysticercus is digested and the scolex is released, which attaches to the intestinal mucosa and starts budding off segments, which reach a length of 2 to 3 meters [5, 6]. The worm usually resides in the upper jejunum and may live for decades [6]. The *Taenia solium* scolex has got hooks and four suckers, it is globular in shape, the mature segment has two large and one small lobe in the ovary and the testis has 150 to 200 follicles. The gravid segment has 7 to 12 lateral uterine branches on each side and the vaginal sphincter is absent [1]. Infestation with the adult worm can be detected by finding eggs or segments in the perianal scrapings or in the faeces [4, 5]. Cysticercus cellulosae is the larval form of *Taenia solium*. These larvae primarily develop in the tissues of pigs and also in the tissues of human beings. They live for about eight months in the flesh and later get calcified. Unlike cysticercus bovis (the larval form of *Taenia saginata*) cysticercus cellulosae can develop in humans [1]. The infective form in this situation is the egg, which is acquired by the consumption of contaminated water or vegetables or by auto infection due to unhygienic habits or the process of reverse peristalsis in the human intestine [1]. The liberated embryos penetrate the mucosa to reach any other part of the body through the blood. They develop into cysticercus cellulosae in the subcutaneous tissue, the muscles, the brain and the eye [1]. The larvae cannot develop further and hence an infection in humans is a dead end for the larvae [1]. The prevention involves the awareness of the disease and the practice of good sanitary and personal hygiene. The ingestion of vegetables whose growth is fortified with sewage should be avoided [5]. Adequate requirements for human sewage disposal should be followed [5]. One of the most important means of prevention is the adequate cooking of pork meat at least at 65 degree centigrade, which is lethal for the larvae [5, 6]. The drug of choice for tapeworm infestation is a single dose of Praziquantel 10 to 20mg per kg body weight or Niclosamide 2 grams as a single dose, which is chewed as an alternative. The patient is observed for several months, as a new worm can regenerate if the scolex or a minute piece of neck remains viable [7, 8].

CONCLUSION

An infestation with tape worm should be considered in cases of abdominal pain and guarding in endemic areas. Prevention is better than cure.

REFERENCES

- [1] Karyakarte R, Damle A. Medical Parasitology In: Cestodes (*Tape worm*) infection, 3rd Ed, Arunabha Sen, Kolkata; 2005: p 110-116.
- [2] Khan Z. Small intestinal perforation which is caused by tape worm. *Pakistan Journal of Surgery* 2007; 23/ 1: 73-75.
- [3] Abu Salem OT, Hassan MA. Acute abdomen and *Taenia solium* peritonii. *Kuwait Medical Journal* 2003 Dec; 299-300.
- [4] Chatterjee KD. Parasitology, protozoology and helminthology, In: *Cestoidea, taenia saginata*, 12th Ed Chatterjee Medical Publishers, Calcutta, 1997; p 116-120.
- [5] Garcia LS. Diagnostic Medical Parasitology, In: *Intestinal Cestodes*,

4th Ed, ASM Press USA; 2001: p 368-377.

- [6] Andreassen J. Intestinal tape worms In: *Topley and Wilsons Parasitology*, Volume-5, Chapter 27, 9th Ed, Georgina Bentliff Oxford University, London; 1998: p 539-548.

- [7] James WT, Leslie TW. Anthelmintic drugs, In: *Good man and Gillman's Pharmacological Basis of Therapeutics*, 10th Ed, McGraw

Hill Comp, New York; 2001: p 1123-1130.

- [8] McPhee SJ, Papadakis MA. Current Medical Diagnosis and Treatment. *Helminthic infections, Cestode infection*, 49th Ed, The McGraw Hill Comp, New York; 2010: p 1376-1377.

AUTHOR(S):

1. Dr. Narayan Shrihari
2. Dr. Mariraj J.
3. Dr. Kumudini T.S.
4. Dr. Krishna S.

PARTICULARS OF CONTRIBUTORS:

1. Corresponding Author.
2. Professor, MD (Microbiology),
Vijayanagar Institute of Medical Science, Bellary,
Karnataka, India.
3. Tutor, D.Bact (Diploma in Microbiology)
Vijayanagar Institute of Medical Science, Bellary,
Karnataka, India.
4. Professor and Head, MD (Microbiology)
Vijayanagar Institute of Medical Science, Bellary,
Karnataka, India.

NAME, ADDRESS, TELEPHONE, E-MAIL ID OF THE CORRESPONDING AUTHOR:

Dr Narayan Shrihari. MD (Microbiology)
Assistant Professor, Department of Microbiology
Vijayanagar Institute of Medical Science, Bellary,
Karnataka - 583104
Phone: 09481710655.
E mail: shriharimicro@gmail.com

DECLARATION ON COMPETING INTERESTS:

No competing Interests.

Date of Submission: **Jun 10, 2011**

Date of peer review: **Aug 09, 2011**

Date of acceptance: **Aug 12, 2011**

Date of Publishing: **Oct 05, 2011**